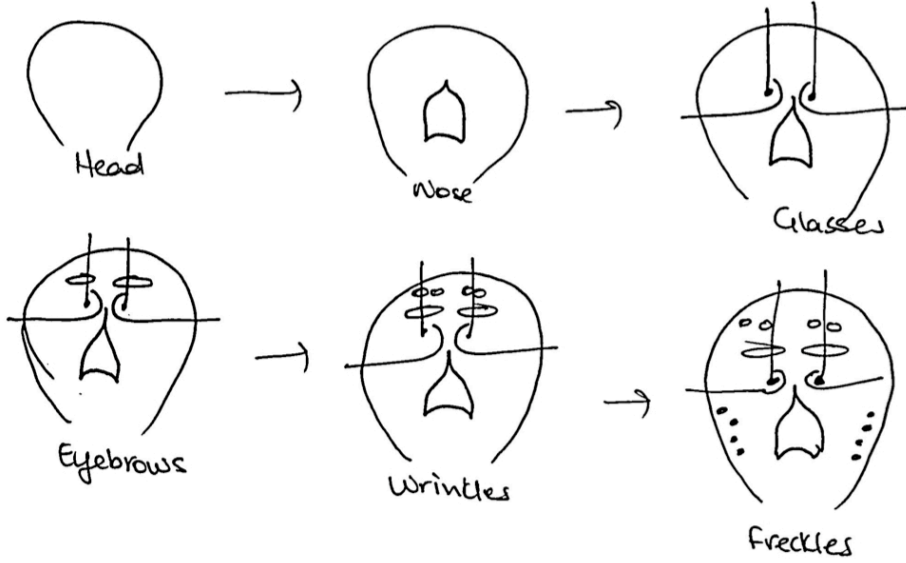


How to Draw the Lower Pons at Level of CN 6 & 7

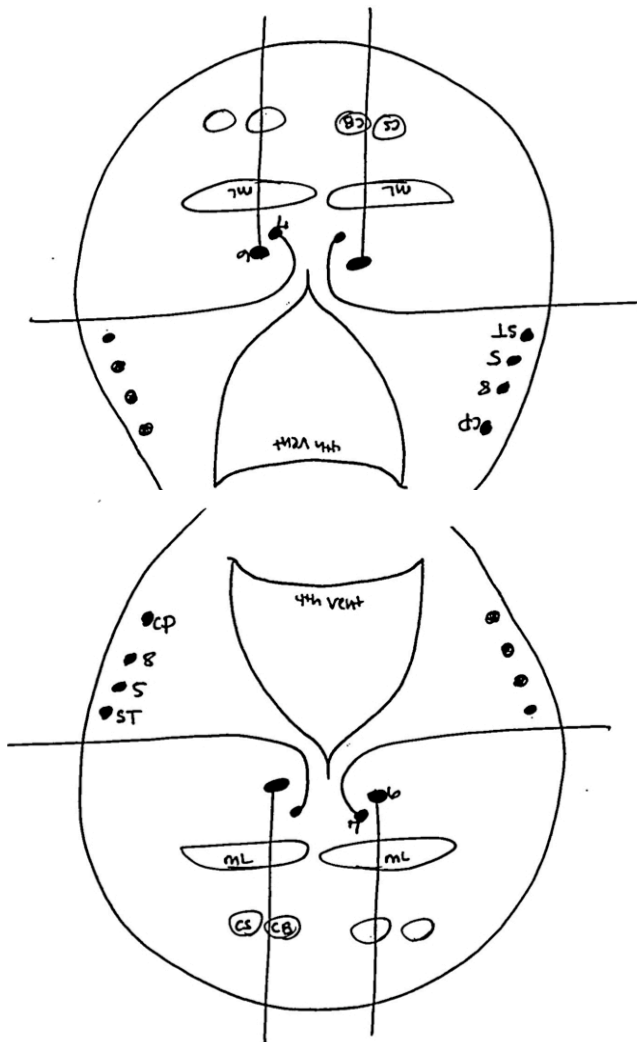
by Dr. Sabrina Gupta

Pons →



Draw the pons quickly for the exam to figure out all the pontine syndromes!

www.Baronerocks.com



The Nerdy Chicken!!!

CP stands for Cerebellar Peduncle
 ST is Spinothalamic Tract
 ML is Medial Lemniscus
 CB is Corticobulbar
 CS is Corticospinal
 5,6,7,8 are the nerves